

## Ointment in anterior chamber after cataract surgery

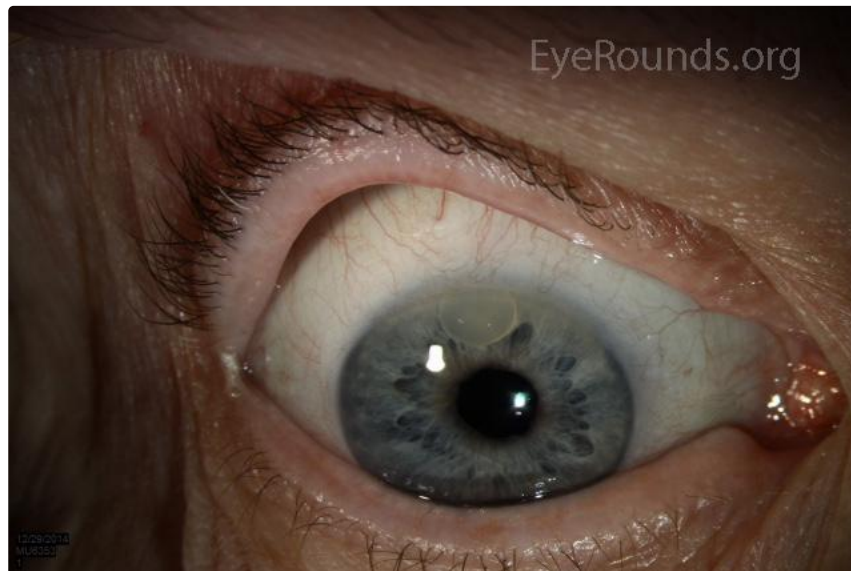Category(ies): [Cataract](#), [Lens](#)

Contributor: [Jeffrey Welder, MD](#)



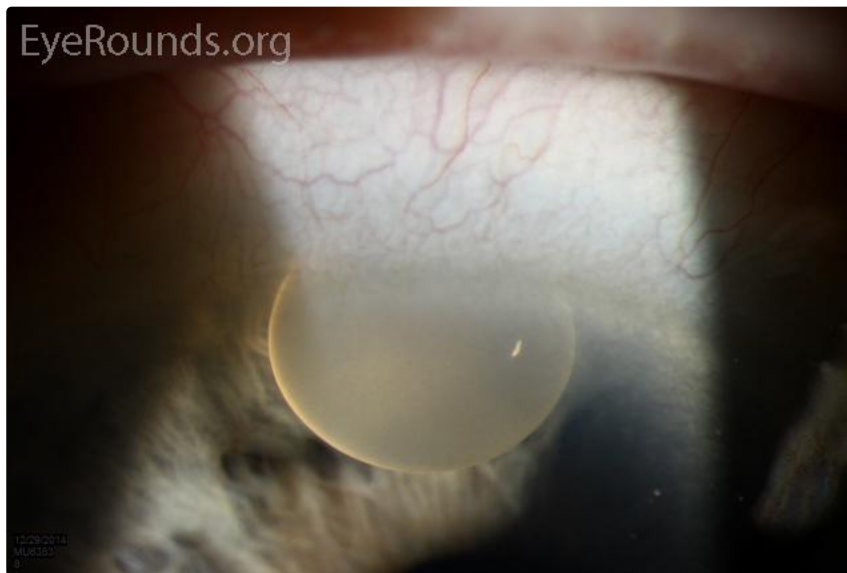
A patient presented one month following uncomplicated cataract surgery due to the presence of a buoyant tan substance in the anterior chamber which was present since postoperative day one. This was felt to represent Maxitrol® ointment wicked through a short wound into the eye. Remarkably, there was no anterior chamber inflammation.

The patient was taken to the operating room and the prior clear corneal incision was used to burp the ointment from the eye followed by irrigation of the anterior chamber.



[Enlarge](#)

[Download](#)



 Enlarge

 Download

### Image Permissions:



Ophthalmic Atlas Images by [EyeRounds.org](#), [The University of Iowa](#) are licensed under a [Creative Commons Attribution-NonCommercial-NoDerivs 3.0 Unported License](#).

### Address

University of Iowa  
Roy J. and Lucille A. Carver College  
of Medicine  
Department of Ophthalmology and  
Visual Sciences  
200 Hawkins Drive  
Iowa City, IA 52242

[Support Us](#)

### Legal

Copyright © 2019 The University of  
Iowa. All Rights Reserved  
[Report an issue with this page](#)  
[Web Privacy Policy](#) |  
[Nondiscrimination Statement](#)

### Related Links

[Cataract Surgery for Greenhorns](#)  
[EyeTransillumination](#)  
[Gonioscopy.org](#)  
[Iowa Glaucoma Curriculum](#)  
[Iowa Wet Lab](#)  
[Patient Information](#)  
[Stone Rounds](#)  
[The Best Hits Bookshelf](#)

### EyeRounds Social Media

Follow



[Receive notification of new cases,  
sign up here](#)  
[Contact Us](#)  
[Submit a Suggestion](#)